



Performance of the Ambu aScope3 in Difficult to Intubate Patients

Ann Melookaran, MD and William Rosenblatt, MD

Department of Anesthesiology, Yale University School of Medicine, New Haven, CT 06520



INTRODUCTION

The development of inexpensive CMOS imaging technology spurred the innovation of disposable, video-based tracheal intubation devices. In 2010 the Ambu corporation (Denmark) released the aScope – a single-patient use flexible intubation scope (FIS). Users of the first generation aScope noted poor image quality and insufficient capacity to remove secretions via the working channel. In February 2014 the third generation aScope became available in the United States, accompanied by claims of improved functionality by the manufacturer.

METHODS

We evaluated the aScope3 for its ergonomics and function in a non-randomized, non-blinded, non-controlled cohort of 10 patients evaluated as “difficult to intubated” based on historical and physical exam findings. An awake or post-anesthetic induction technique was chosen by the anesthesiologist assigned to the case (primary anesthesiologist). A traditional FIS was available in the operating room at all times. The anesthesiologist was instructed

METHODS (Cont'd)

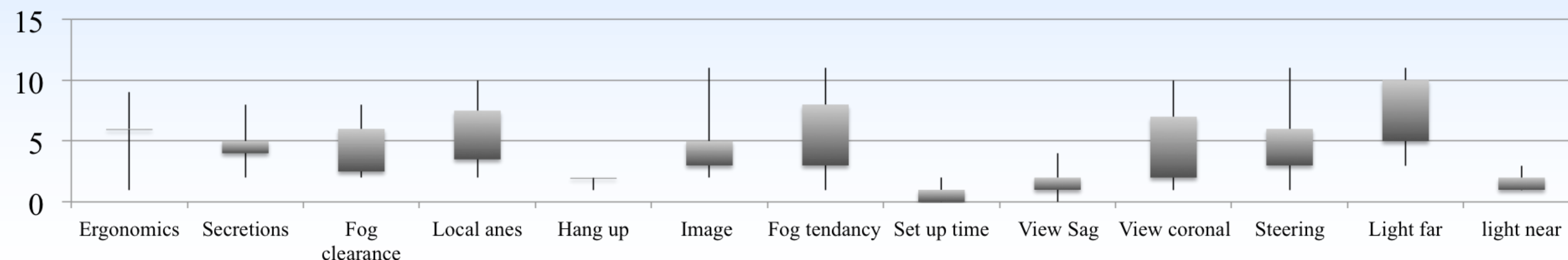
to abandon the aScope3 in favor of the traditional FIS if felt clinically appropriate. After tracheal intubation, the anesthesiologist completed a 12 question visual analogue scale (1 to 15) as well as noted the incidence of tracheal tube hang-up during ETT insertion, aScope and ETT size, and induction technique. All intubations were recorded with the aScope3’s internal memory capabilities. Recordings of all intubations were reviewed by an independent anesthesiologist regarding image and lighting quality. Primary and independent anesthesiologists’ scores were compared with Wilcoxon signed–rank test.

RESULTS

One patient was removed from analysis due to incomplete data. All patients were intubated successfully. In no instance did the anesthesiologist abandon aScope3 use. There was no difference between the primary and independent anesthesiologists’ the scoring of image quality, near and far lighting. The 1st and 3rd quartiles, maximum and minimum scores are reported in the figure. Hang-up occurred in 2 cases when there was more than a 4mm discrepancy in ETT vs aScope3 size.

DISCUSSION

We have demonstrated the use of the aScope3 in difficult to intubate (DI) patients. The pre-operative diagnosis of DI is often subjective – alternative procedures are often undertaken without the objective testing of whether or not difficulty will occur. Though the aScope3 performed comparably to a multi-patient, durable FIS our results cannot be generalized to all difficult airway patients. The improved image and lighting quality and secretion removal capacity, the single-patient resourcing, and lack of repair costs and inconveniences make the incorporation of the aScope3 a practical and attractive alternative or complement to the traditional FIS.



PREOPERATIVE DI FACTOR	N
Airway mass	2
Prior airway surgery	1
Prior airway radiation	3
Subgottic stenosis	2
Trismus	2
Unstable C-Spine	1
Awake intubation	3